

# Touch Imprint Cytology in Oral Cancer Diagnosis: A Narrative Review

SHRADHA JAISWAL<sup>1</sup>, SUMIRAN SINHA<sup>2</sup>, BHUPESH BAGULKAR<sup>3</sup>, ATUL BHAT<sup>4</sup>, RUPA SHARMA<sup>5</sup>

## ABSTRACT

Touch Imprint Cytology (TIC) is a simple, economical, and cost-effective method that can be used as a rapid tool for tissue diagnosis. It has been used for the intraoperative diagnosis of cancer, evaluation of surgical cut margins, evaluation of sentinel lymph nodes, diagnosis of head and neck lesions, and postmortem diagnosis. Intraoperative diagnosis includes both frozen section and TIC, which provide rapid pathological consultation. Brush biopsy can also be used for cytological diagnosis and acts as an adjunct to histopathological and TIC diagnosis. It has been found that TIC yields satisfactory and adequate material for diagnosis, allowing early counselling and preparation of the patient for further processes without having to wait for the results of histopathology. As technology continues to evolve, ongoing research aims to enhance the utility and accuracy of TIC in oral cancer diagnosis. Advancements in imaging techniques, such as confocal microscopy and molecular analysis of TIC samples, hold promise for improving diagnostic sensitivity and specificity.

**Keywords:** Frozen section, Histopathological technique, Papanicolaou stain

## INTRODUCTION

The most common type of cancer encountered in India is oral cancer, and among these, oral squamous cell carcinoma is the most common histological type. Biopsy is the most relied-upon option for the diagnosis of such cancers. However, the entire procedure of taking a biopsy, processing it, and obtaining a diagnosis requires a time span of 3 to 7 days, depending on the resources available, which is quite long [1]. Advancements in diagnostic techniques have introduced less time-consuming methods like TIC, which have shown promising results in the detection and diagnosis of oral cancer. TIC is a process similar to cytology that can be used intraoperatively to reach a definitive diagnosis in a short time period, as it conserves tissue without the need to freeze or process it. Conventional cytology techniques involve scraping the surface, i.e., exfoliative cytology, or Fine Needle Aspiration Cytology (FNAC) for deep-seated cystic lesions where fluid is withdrawn. In contrast, TIC involves the removal of the entire lesion, which is then imprinted on a glass slide prior to processing.

TIC was first introduced by Tribe in 1973 [2] and involves gently cleaning the cut surface of the biopsy specimen with dry gauze to remove any excess blood or saline. The freshly cut surface of the specimen is then gently touched on the glass slide, avoiding a gliding movement. The pressure applied for imprinting varies with the consistency of the specimen. Smears are then quickly fixed in 95% alcohol to avoid air-drying artifacts and are usually stained with a variant of Papanicolaou's stain. The major difference between TIC and other cytological techniques is that exfoliative cytology uses exfoliated cells or scraped superficial cells from the lesion for diagnosis, while FNAC uses a wide-bore needle to draw out fluid for diagnosis. In contrast, TIC utilises the cut tissue surface of a biopsy specimen for cell yield and diagnosis. Hence, TIC has a distinct advantage over exfoliative cytology in that the chances of visualising dysplastic cells are greater in TIC compared to exfoliative cytology and FNAC [3].

Several studies have been performed to depict the reliability of the TIC technique in reaching a diagnosis [4]. A study performed by Tanabe N et al., on TIC for the diagnosis of PitNET surgical margins showed that TIC has an accuracy of 75% in margin evaluation [4]. Another study conducted by Randive R et al., on TIC of lymph nodes and their histopathological correlation revealed a sensitivity

of 60% and specificity of 100% in diagnosing malignant lesions, along with a 100% positive predictive value in diagnosing non neoplastic lesions [5]. Additionally, Naveed H et al., carried out a study on the diagnostic accuracy of touch imprint for head and neck malignancies (upper aerodigestive tract), which demonstrated a sensitivity of 96% and specificity of 100% [6]. Thus, these studies have sparked interest among clinicians in exploring this technique and its utility as a rapid screening tool to provide a general guideline for mentally preparing a patient prior to receiving the histopathological report of a biopsy. Therefore, this review paper aims to provide a concise overview of the TIC process, covering its various aspects, advantages, limitations, and future scope.

## Principle

The TIC is the microscopic examination of tissue cellular material for the diagnosis of diseases, particularly cancer. It is used as an adjunct to histological diagnosis, which relies on the architecture of the tissue to help determine the disease process. In contrast, cytological diagnosis relies on the examination of individual cells and their morphology to provide clues about the cell's health and activity [6].

## Uses

The TIC has been extensively used, and many researchers have found it useful in determining the surgical resection margins of tumours [7], diagnosing malignant and benign tumours [8], diagnosing skin lesions like basal cell carcinomas and tumours like meningiomas and gliomas [9-11], diagnosing metastatic tumours, and assessing salivary gland tumours like pleomorphic adenomas and mucoepidermoid carcinomas [12,13].

## Advantages

Unlike biopsies that require tissue removal, TIC involves only the collection of superficial cells from the lesion, minimising patient discomfort and reducing the risk of complications. TIC provides rapid preliminary results, allowing for immediate on-site evaluation by a pathologist. This quick turnaround time can expedite the diagnostic process and facilitate the prompt initiation of treatment. TIC is a cost-effective diagnostic tool compared to traditional biopsies, as it requires minimal equipment and can be performed in outpatient settings without the need for anaesthesia or surgical facilities. TIC can

be performed in various clinical settings, including primary care offices, dental clinics, and community health centres, making it accessible to a broader population, especially in underserved areas where access to specialised diagnostic facilities may be limited [12-14].

### Pitfalls

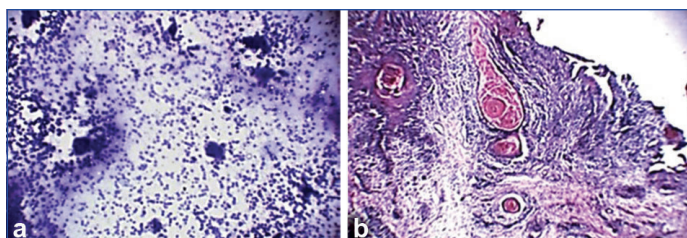
One of the major pitfalls of using this technique is that superficial biopsies can result in false negative results. Focal tumour extensions may lead to false negatives if the area of focal extension has been missed by the operator. In well-differentiated tumours, loss of cohesion is less evident, and there is also less cellularity seen at the margins, which can lead to a failure of tumour cell adhesion to the glass slides and result in a negative diagnosis. TIC provides only a superficial assessment of cellular material, which may not always capture deeper tissue changes or architectural abnormalities present in certain lesions. The interpretation of TIC slides relies heavily on the expertise of the examining pathologist, and there may be subjective variations in diagnostic interpretation among different observers. The invasion of the tumour cannot be assessed, as it only shows the presence or absence of dysplastic cells [14].

### TIC vs Frozen Section

The TIC is an excellent tool for rapid intraoperative diagnosis, alongside frozen section analysis. In comparison, frozen sections have shown some operative complications, like freezing artifacts, low cost-effectiveness, and the requirement for expertise in operating the cryostat machine. TIC, on the other hand, is a very simple, inexpensive, and easy-to-perform procedure that requires a pathologist's expertise in cytology interpretation [14,15]. A study performed by Scucchi LF et al., on 2,250 samples found that the sensitivity and specificity for frozen section were 89.9% and 97.95%, respectively, while for TIC, they were 94.9% and 96.8% [16]. A similar study by Guarda LA reported an accuracy of 98.4% for TIC and 99.2% for frozen section [17]. Touch cytology provides better cellular details and fewer artifacts. The diagnostic accuracy in distinguishing between benign and malignant lesions when combining TIC and frozen section was 100%. Touch imprints prepared from fresh surgical specimens yield excellent cytological clarity and, when used intraoperatively, can provide valuable information where frozen section interpretation is equally important [18-20].

### TIC versus Histopathological Technique

Histopathology is the gold standard for diagnosing any lesion. However, touch imprint preparation has been used as an adjunct technique to histopathology for the diagnosis of various cancers. Studies have found that cytological preparations play an important role in the perioperative assessment of malignant lesions and can be used for screening and diagnostic purposes. The commonly used cytological preparations for diagnostic analysis include touch imprint, scrape, squash, and fine needle aspirates. TIC has the advantage of relative ease in performing the procedure; it is a rapid procedure that does not alter tissue or produce undesirable artifacts, providing excellent cytological clarity [Table/Fig-1]. Histopathology can be time-consuming and may not be useful in intraoperative consultations where quick decisions are required. The use of frozen sections for intraoperative consultation is widely adopted; however, it employs expensive equipment. TIC preparation does not affect normal histopathological processing since fresh surgical specimens are first used to make cytological preparations before the tissue is processed into paraffin-embedded sections. It is possible to assess tumour cells using touch imprint preparation, as tumour cells are generally characterised by reduced cohesiveness, which allows them to be present in tissue fluid more readily. Thus, the tissue surface may be selectively enriched with detached tumour groups, providing a unique source of cytological information [20-23].



**[Table/Fig-1]:** a) TIC picture of oral squamous cell carcinoma showing cells with dysplastic features under 10x view; b) Histopathological picture of oral squamous cell carcinoma obtained from the biopsy sample of the same patient under 10x shows its well-differentiated variant. (Images from left to right).

Source: Department of Oral and Maxillofacial Pathology and Microbiology, Sri Aurobindo College of Dentistry

### Limitation(s)

Despite the numerous advantages, touch imprint has certain limitations as well. Oral cancer is one of the most common cancers affecting the oral cavity. However, this technique cannot be used for the diagnosis of oral cancer, as a superficial biopsy or one that has not been taken from a representative site will result in a zero yield of tumour cells [23,24]. Another drawback is that the technique only identifies dysplastic cells and not tumour architecture; hence, differentiating between epithelial dysplasia and cancer is not possible using this technique [25-27].

### CONCLUSION(S)

TIC represents a valuable adjunctive tool in the diagnosis and management of oral cancer. Its simplicity, cost-effectiveness, and accessibility make it an attractive option for clinicians involved in oral cancer screening and diagnosis. However, further studies are required to optimise its performance and integration into routine clinical practice, ultimately improving outcomes for patients with oral cancer.

### REFERENCES

- Adhya AK, Kar M, Mohanty R. Touch imprint cytology: A rapid and accurate method for diagnosis of oral cancer. *Acta Cytol.* 2019;63(5):411-16.
- Haque A. Touch impression cytology versus frozen section as intraoperative consultation diagnosis. *Int J Pathol.* 2004;2(2):63-70.
- Hahn PF, Eisenberg PJ, Pitman MB, Gazelle GS, Mueller PR. Cytopathologic touch preparations (imprints) from core needle biopsies: Accuracy compared with that of fine-needle aspirates. *AJR.* 1995;165:1277-79.
- Tanabe N, Inoshita N, Ishida A, Kato M, Yoshimoto H, Shiramizu H, et al. Touch imprint cytology is useful for the intraoperative pathological diagnosis of PitNETS' surgical margins. *Brain Tumor Pathol.* 2023;40(4):215-21.
- Randive R, Vishwanathan V, Dharwadkar A, Bavikar R, Gore C, Palal D, et al., Touch Imprint cytology of lymph nodes and their histopathological correlation. *J Pharmaceutical Negative Results.* 2022;13(9):8050-60.
- Naveed H, Abid M, Hashmi AA, Edhi MM, Sheikh AK, Mudassar G, et al. Diagnostic accuracy of touch imprint cytology for head and neck malignancies: A useful intraoperative tool in resource limited countries. *BMC Clin Pathol.* 2017;17:25.
- Creager AJ, Shaw JA, Young PR, Geisinger KR. Intraoperative evaluation of lumpectomy margins by imprint cytology with histologic correlation. A community hospital experience. *Arch Pathol Lab Med.* 2002;126:846-48.
- Ku NN, Cox CE, Reintgen DS, Greenberg HM, Nicosia SV. Cytology of lumpectomy specimens. *Acta Cytol.* 1991;35(4):417-21.
- Monabati A, Kumar PV, Kamkarpour A. Intraoperative cytodagnosis of metastatic brain tumors confused clinically with brain abscess. A report of three cases. *Acta Cytol.* 2000;44(3):437-41.
- Feinberg MR, Bhaskar AG, Bourne P. Differential diagnosis of malignant lymphoma by imprint cytology. *Acta Cytol.* 1980;24(1):16-25.
- Hentry-Tillman RS, Korourian S, Rubio IT, Johnson AT, Mancino AT, Massol N, et al. Intraoperative touch preparation for sentinel lymph node biopsy: A 4-year experience. *Ann Surg Oncol.* 2002;9(4):321-23.
- Tworek-JA, Giordano-TJ, Michael-CW. Comparison of intraoperative cytology with frozen sections in the diagnosis of thyroid lesions. *Am J Clin Pathol.* 1998;110(4):423-24.
- Belleannee G, Verdebout J, Feoli F, Trousette H, de Mascarel A, Verhest A. Role of cytology and frozen sections in the intraoperative examination of the thyroid: Comparison of two experiences. *Clin Exp Pathol.* 1999;47(6):273-77.
- Westra WH, Pritchett DD, Udelsman R. Intraoperative confirmation of parathyroid tissue during parathyroid exploration a retrospective evaluation of the frozen section. *Am J Surg Pathol.* 1998;22(5):538-44.
- Shidham VB, Asma Z, Rao RN, Chavan A, Machhi J, Almagro U, et al. Intraoperative cytology increases the diagnostic accuracy of frozen sections for the confirmation of various tissues in the parathyroid region. *Am J Clin Pathol.* 2002;118(6):895-902.

- [16] Scucchi LF, Stefano DD, Cosentino L, Vecchione A. Value of cytology as an adjunctive intraoperative diagnostic method. An audit of 2,250 consecutive cases. *Acta Cytol.* 1997;41(5):1489-96.
- [17] Guarda LA. Intraoperative cytologic diagnosis: Evaluation of 370 consecutive intraoperative cytologies. *Diagn Cytopathol.* 1990;6:304-07.
- [18] Agarwal A, Bholra N, Kambala R, Borle R. Touch imprint cytology: Can it serve as an alternative to frozen section in intraoperative assessment of cervical metastasis in oral squamous cell carcinoma. *J Oral Maxillofac Surg.* 2019;77(5):994-99.
- [19] Takekawa Y, Kinukawa N, Nemoto N, Sakurai I, Komatsu K, Seki T, et al. Usefulness of cytology applied simultaneously to frozen section at rapid intraoperative diagnosis of intracranial tumors. *Rinsho Byori.* 1998;46(9):954-58.
- [20] Geetha L, Astekar M, Ashok KN, Sowmya GV. Touch imprint cytology: A rapid diagnostic tool for oral squamous cell carcinoma. *Biotech Histochem.* 2015;90(5):348-52.
- [21] Yadav GS, Donoghue M, Tauro DP, Yadav A, Agarwal S. Intraoperative imprint evaluation of surgical margins in oral squamous cell carcinoma. *Acta Cytol.* 2013;57(1):75-83.
- [22] Zafar A, Sherlin HJ, Jayaraj G, Ramani P, Don KR, Santhanam A. Diagnostic utility of touch imprint cytology for intraoperative assessment of surgical margins and sentinel lymph nodes in oral squamous cell carcinoma patients using four different cytological stains. *Diagn Cytopathol.* 2020;48(2):101-10.
- [23] Geelhoed GW, Silverberg SG. Intraoperative imprints for the identification of parathyroid tissue. *Surgery.* 1984;96(6):1124-31.
- [24] Savargaonkar P, Farmer PM. Utility of intraoperative consultations for the diagnosis of central nervous system lesions. *Ann Clin Lab Sci.* 2001;31(2):133-39.
- [25] Ghandur-Mnaymneh L, Paz J. The use of Touch preparations (tissue imprints) in the rapid intraoperative diagnosis of metastatic lymph node disease in cancer staging procedures. *Cancer.* 1985;56(2):339-44.
- [26] Chowdhury A, Bhattacharya R, Panda J, Chakrabarty D. Toluidine blue stain as a rapid onsite tool for preliminary diagnosis in imprint smears of bronchoscopic biopsy: A cyto histopathological correlation. *J Lab Physicians.* 2023;15:562-66.
- [27] Dogan S, Becker JC, Rekhman N, Tang LH, Nafa K, Ladanyi M, et al. Use of touch imprint cytology as a simple method to enrich tumor cells for molecular analysis. *Cancer Cytopathol.* 2013;121(7):354-60.

#### PARTICULARS OF CONTRIBUTORS:

1. Professor and Head, Department of Oral and Maxillofacial Pathology and Microbiology, Sri Aurobindo College of Dentistry, Indore, Madhya Pradesh, India.
2. Postgraduate Student (2<sup>nd</sup> Year), Department of Oral and Maxillofacial Pathology and Microbiology, Sri Aurobindo College of Dentistry, Indore, Madhya Pradesh, India.
3. Professor, Department of Oral and Maxillofacial Pathology and Microbiology, Sri Aurobindo College of Dentistry, Indore, Madhya Pradesh, India.
4. Professor, Department of Oral and Maxillofacial Pathology and Microbiology, Sri Aurobindo College of Dentistry, Indore, Madhya Pradesh, India.
5. Postgraduate Student (1<sup>st</sup> Year), Department of Oral and Maxillofacial Pathology and Microbiology, Sri Aurobindo College of Dentistry, Indore, Madhya Pradesh, India.

#### NAME, ADDRESS, E-MAIL ID OF THE CORRESPONDING AUTHOR:

Dr. Sumiran Sinha,  
Harshringar Block C, Room No. 608, Sri Aurobindo Institute of Medical Sciences,  
Indore-453555, Madhya Pradesh, India.  
E-mail: sinha.sumirann@gmail.com

#### PLAGIARISM CHECKING METHODS: [\[Jain H et al.\]](#)

- Plagiarism X-checker: Apr 17, 2024
- Manual Googling: May 07, 2024
- iThenticate Software: Sep 16, 2024 (8%)

#### ETYMOLOGY: Author Origin

EMENDATIONS: 8

#### AUTHOR DECLARATION:

- Financial or Other Competing Interests: None
- Was informed consent obtained from the subjects involved in the study? NA
- For any images presented appropriate consent has been obtained from the subjects. NA

Date of Submission: **Apr 17, 2024**  
Date of Peer Review: **May 08, 2024**  
Date of Acceptance: **Sep 17, 2024**  
Date of Publishing: **Nov 01, 2024**